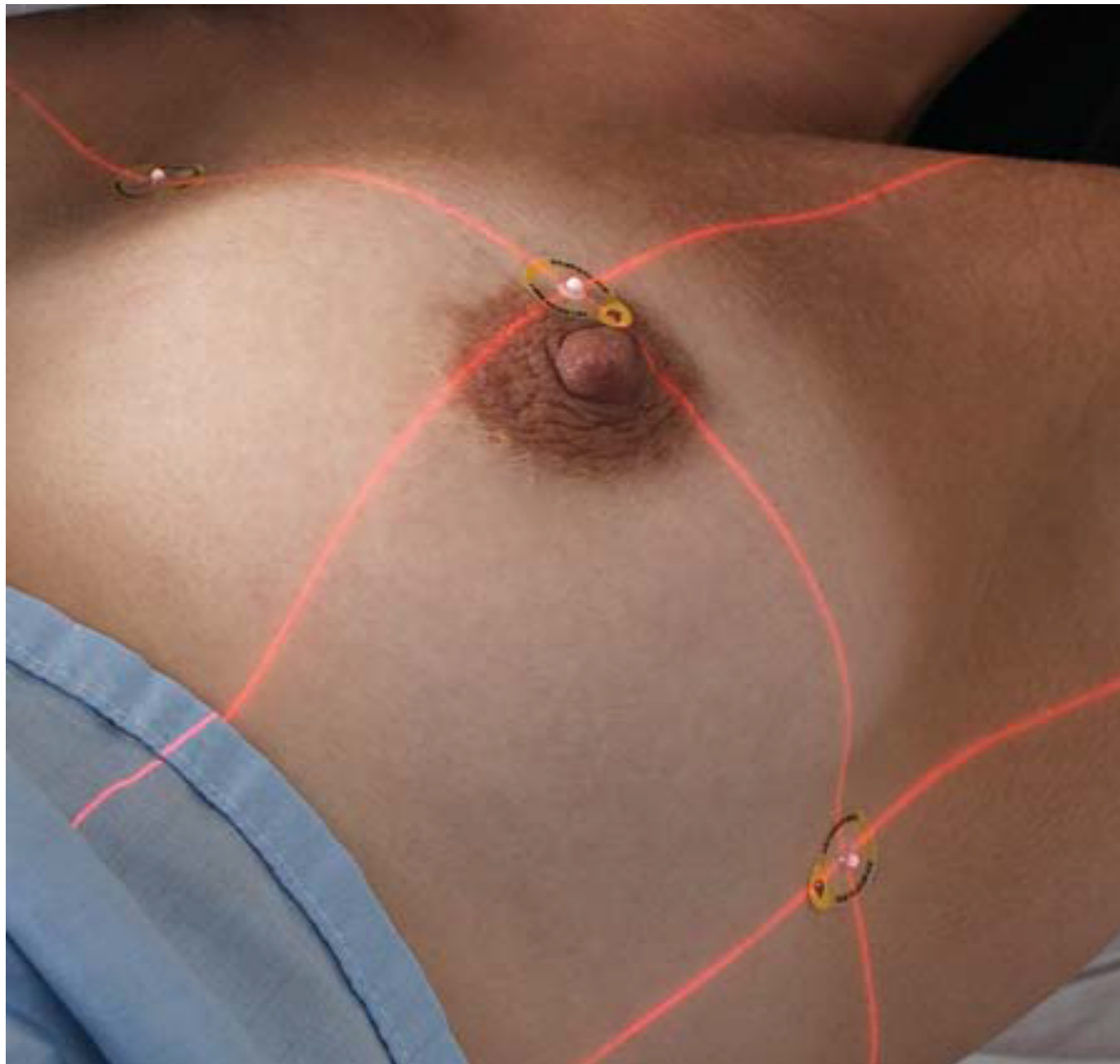
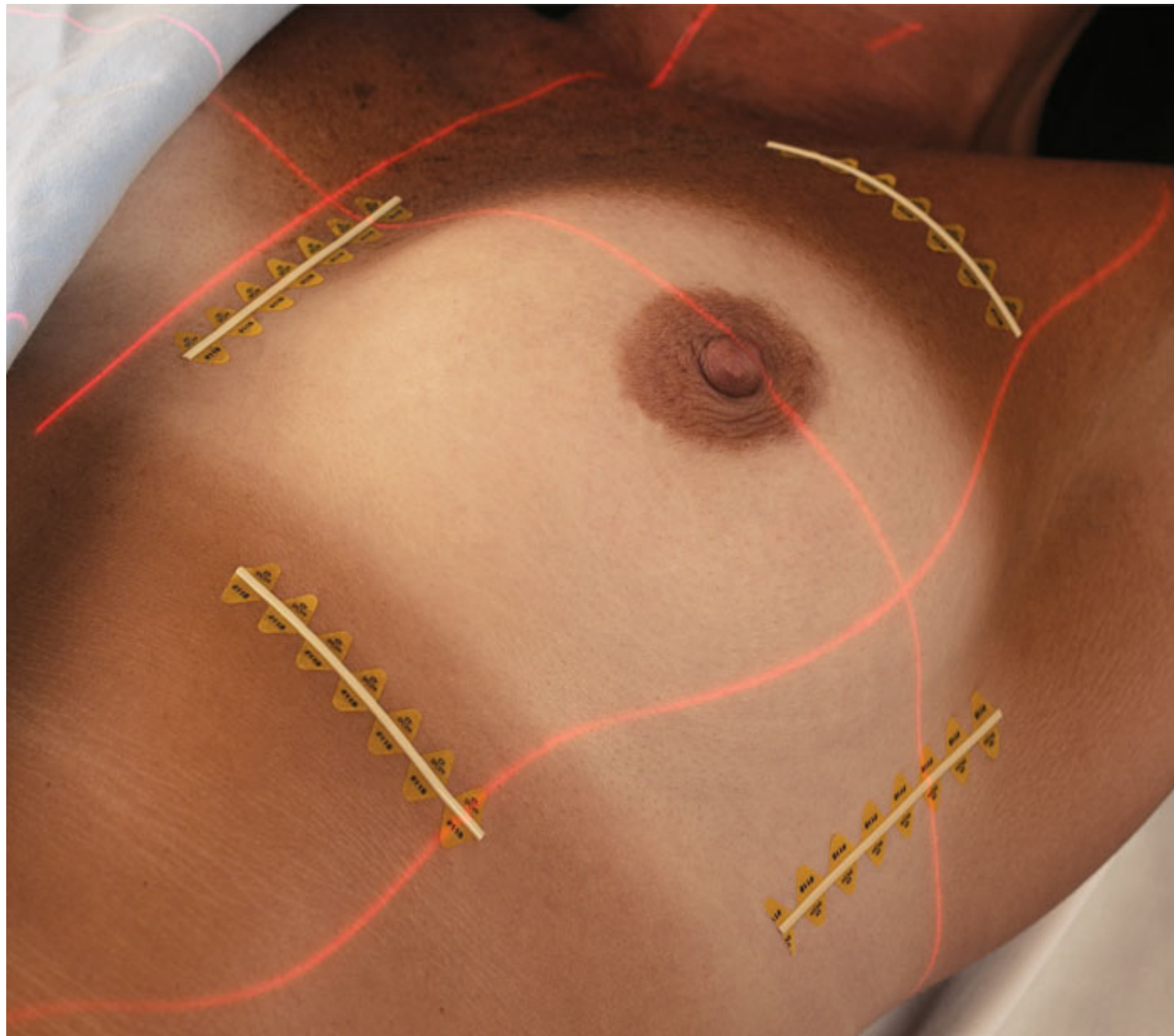


Image Examples for Radiation Therapy Skin Marker Photo Shoot

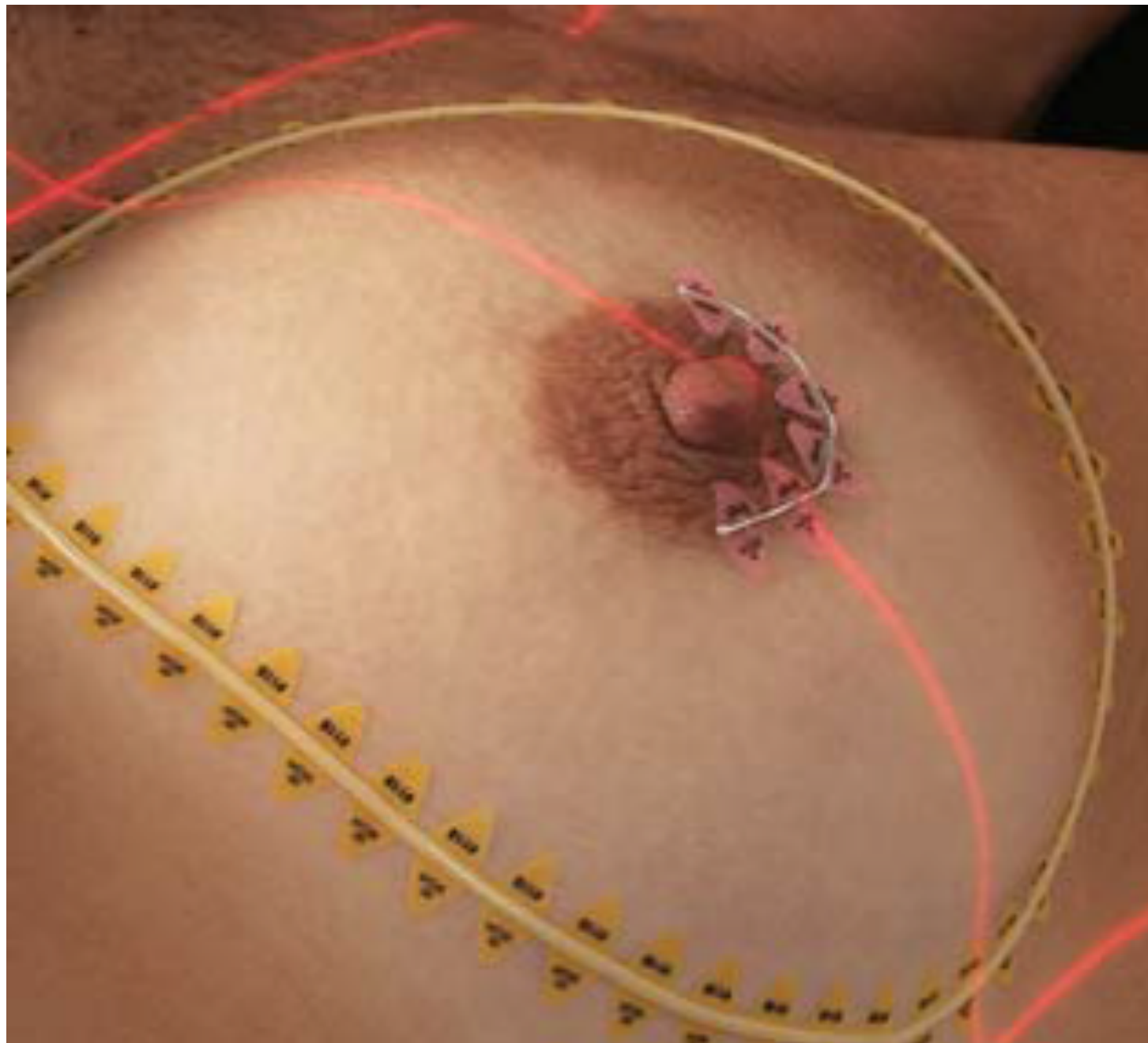
12/2020



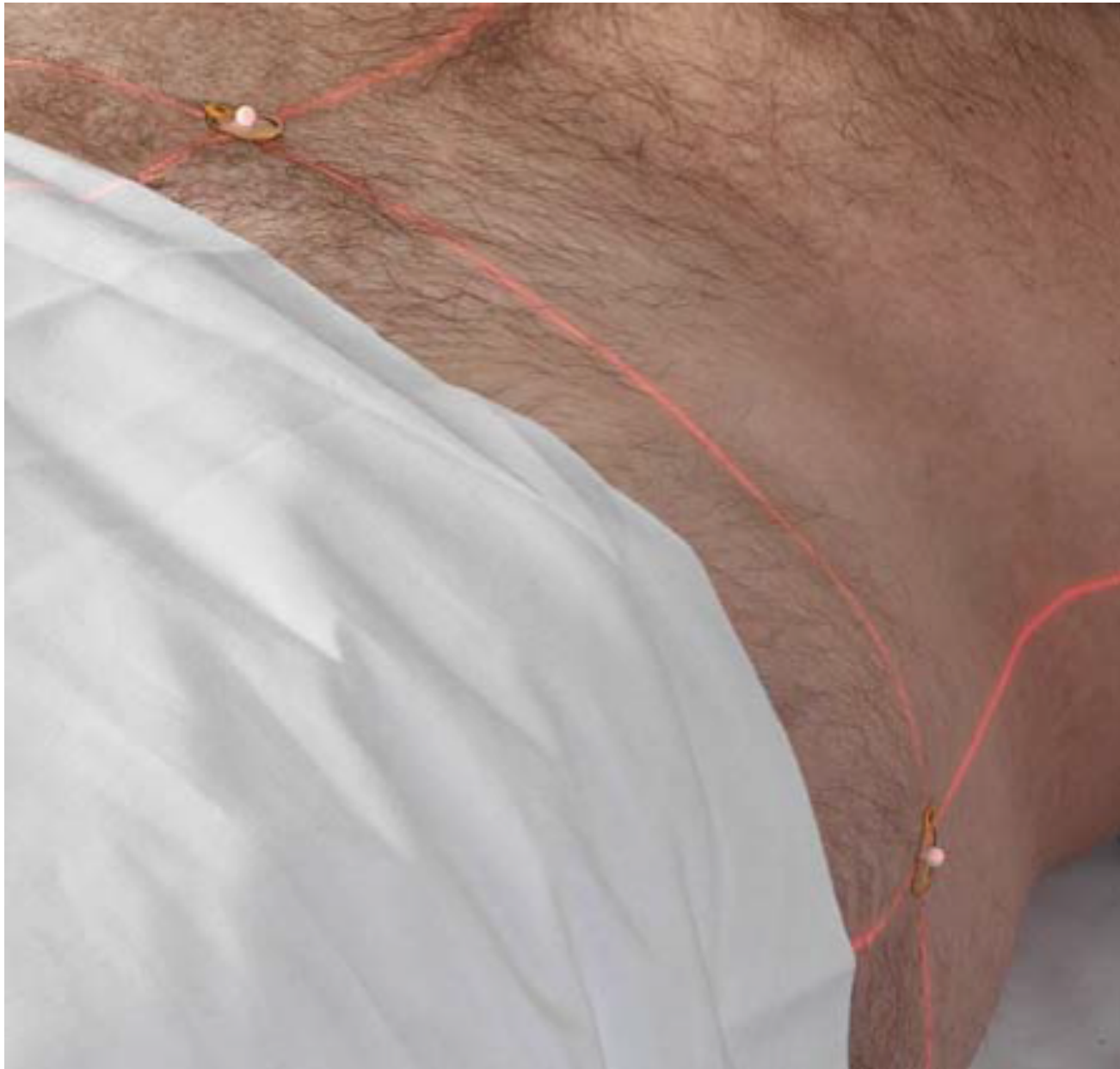3 Point Set-up w 4mm CT-Pellets



Field Borders and Breast Tangents



Breast circled w CT-Line, scar marked w S-Spot



Abdomen 3 point set-up w 4mm CT Pellet